

Otterbein University

## Digital Commons @ Otterbein

---

Nursing Student Class Projects (Formerly MSN)

Student Research & Creative Work

---

2016

### Postoperative Ileus

Jamie Pearson

jamie.pearson@otterbein.edu

Follow this and additional works at: [https://digitalcommons.otterbein.edu/stu\\_msn](https://digitalcommons.otterbein.edu/stu_msn)



Part of the [Nursing Commons](#)

---

#### Recommended Citation

Pearson, Jamie, "Postoperative Ileus" (2016). *Nursing Student Class Projects (Formerly MSN)*. 189.  
[https://digitalcommons.otterbein.edu/stu\\_msn/189](https://digitalcommons.otterbein.edu/stu_msn/189)

This Project is brought to you for free and open access by the Student Research & Creative Work at Digital Commons @ Otterbein. It has been accepted for inclusion in Nursing Student Class Projects (Formerly MSN) by an authorized administrator of Digital Commons @ Otterbein. For more information, please contact [digitalcommons07@otterbein.edu](mailto:digitalcommons07@otterbein.edu).

# Postoperative Ileus

Jamie Pearson, RN

Otterbein University, Westerville, Ohio

## Pathophysiological Processes

### Introduction

The topic of postoperative ileus was chosen because this author has cared for patients with this postoperative complication. This author is a registered nurse on an inpatient surgical unit at a local hospital, and unfortunately postoperative complications are a reality. This author's experience with postoperative ileus includes symptom management of nausea, vomiting, and pain, and the intervention of a nasogastric tube set to suction to decompress the stomach.

This author's goal with this poster is to provide research on postoperative ileus to help others learn more about the pathophysiology of the condition, causes of ileus, symptoms, treatments, and prevention. By learning more on postoperative ileus, healthcare providers will be better prepared to care for postoperative patients to help prevent ileus after surgery and to better care for the patient if they were to develop an ileus. This poster can also serve as an education tool for patients by teaching the patient preventative measures to help protect themselves postoperatively.

In the future as an advanced practice nurse, this author plans to continue to care for surgical patients. Patient education will be an important aspect for prevention of postoperative complications, including ileus. Patients will benefit from understanding preventative strategies to help protect themselves from complications and to prepare for the postoperative recovery period. Improved patient understanding of the surgery and recovery may help to prevent complications and help to improve the quality of life for patients (Hadden, Prince, Schnaekel, Couch, Stephenson, & Wyrick, 2016).

### Signs and Symptoms

Postoperative ileus is an impairment of bowel motility that occurs after surgery. Ileus is a functional obstruction of the bowel, rather than a mechanical obstruction (Lafon & Lawson, 2012). Postoperative ileus can affect the small or large intestine (Fineberg et al., 2014).

Patients may experience the following:

- Discomfort related to the ileus
- Increases in postoperative pain
- Accumulation of gas and fluid in the gastrointestinal tract
- Abdominal distention
- Lack of bowel sounds
- Lack of passing flatus
- Lack of passing stool
- Nausea
- Vomiting
- Delayed absorption of nutrients and medication (Lafon & Lawson, 2012)
- Electrolyte disturbances
- Dehydration (Linari, Schofield, & Horrom, 2011)
- Delayed time to adequate nutrition (Thompson & Magnuson, 2012)
- Diet intolerance (Massey, 2012)
- Decreased mobility
- Morbidity (Fineberg et al., 2014)

Abdominal x-rays may show dilated air filled loops, however this finding is not exclusive to an ileus (Ward, 2012).

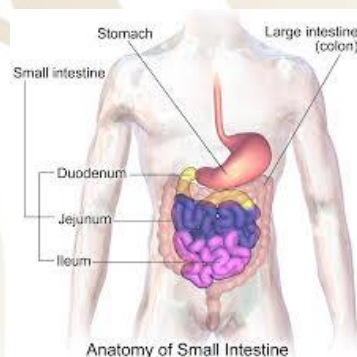


Figure 1- Anatomy of Small Intestine (Blausen.com Staff, 2014a)

### Underlying Pathophysiology and Its Significance

The exact etiology and pathology of a postoperative ileus is not known (Wronski, 2014).

Development of a postoperative ileus is influenced by:

- Autonomic nervous system
- Enteric nervous system
- Hormones
- Neuropeptides
- Inflammation
- Anesthesia inhibits bowel motility with the large intestine affected most often. The upper gastrointestinal region can also experience decreased gastric emptying leading to aspiration, nausea, and vomiting. These areas are often affected because of the impairment to the neural integration (Linari et al., 2011).
- Narcotics decrease bowel motility by binding to peripheral opiate receptors causing impairment (Lafon & Lawson, 2012). Narcotics also decrease the urge to have a bowel movement (Linari et al., 2011).
- Activity level- Patients on bed rest have an increased risk of developing an ileus (Hiranyakas, Bashankaev, Seo, Khaikin, & Wexner, 2011).
- Type of surgery- Abdominal surgery causes inflammation which increases the chance of ileus (Thompson & Magnuson, 2012).

There are many neural pathways in the gastrointestinal tract that are responsible for peristalsis. The three major neurons controlling the activity of the gastrointestinal tract include sensory neurons, interneurons, and inhibitory and excitatory motor neurons (Thompson & Magnuson, 2012).

Ileus usually resolves in three to five days. However, the extended hospital stay increases the patient's risk of other postoperative complications, including pulmonary complications and nosocomial infections (Lafon & Lawson, 2012).

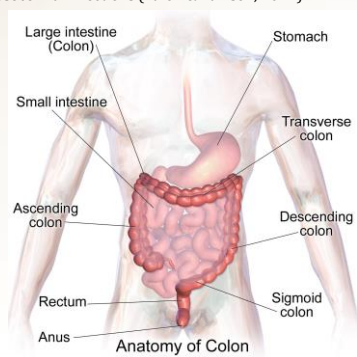


Figure 2- Anatomy of Colon (Blausen.com Staff, 2014b)

## Implications for Nursing Care

Nurses are vital in providing a positive patient experience while striving to give the patient the best outcome possible. Prophylaxis should be provided at every phase of surgery, from preoperative to perioperative to postoperative (Hiranyakas et al., 2011). Due to all of the factors that can cause an ileus, nursing care must be a holistic approach (Lafon & Lawson, 2012).

Ileus can lead to increased:

- Risk of morbidity
- Risk of readmission within 30 days of discharge from a hospital (Bragg, El-Sharkawy, Psaltis, Maxwell-Armstrong, & Lobo, 2015)
- Healthcare costs- estimated at \$1 billion annually in the United States (Lafon & Lawson, 2012)

Medication, surgical techniques, and postoperative nursing care are all important elements of a patient's care to aid in a return of normal gastrointestinal function following surgery or a postoperative ileus. There is currently no method approved by the U.S. Food and Drug Administration to prevent a postoperative ileus (Lafon & Lawson, 2012). Furthermore, there is not one solo medication to resolve an ileus once it occurs because of the multifactorial nature of the condition (Hiranyakas et al., 2011).

Prevention methods of postoperative ileus include:

- Stool softeners
- Adequate fluid intake
- Early ambulation (Linari et al., 2011)
- Monitoring fluid balance to reduce bowel edema which can lead to ileus
- Avoid excess doses of opioids. Non-opioid medications such as NSAIDs and local anesthetics can be beneficial for pain control without aggravating the condition (Lafon & Lawson, 2012).
- Chewing gum- Studies have provided evidence that patients that chewed gum following surgery were able to pass flatus and have a bowel movement sooner than the non-gum-chewing groups. The gum-chewing patients had less incidence of postoperative ileus and a shorter length of stay in the hospital. Less incidence of postoperative ileus led to better patient satisfaction among the gum-chewing patients. This intervention is also referred to as sham feeding. Gum chewing mimics intake of food which activates the efferent gastrointestinal vagus nerve. Gastric acid, pepsin, and pancreatic polypeptide are then produced and secreted which increases gastric motility (Wronski, 2014). Some brands of sugarless gum contain Xylitol which can even have a mild laxative effect on the patient (Forrester, Doyle-Munoz, McTigue, D'Andrea, & Natale-Ryan, 2014).

Interventions for postoperative ileus include:

- Nasogastric suctioning
- Early mobilization of the patient
- Prokinetic agents
- Use of the least invasive surgical method
- Delayed enteral feeding- It is recommended to postpone eating until flatus or bowel movement are present. Then the patient may begin having oral fluids and advancing the diet to solid food as tolerated.
- Pain medication should be used to decrease postoperative pain and the pain associated with an ileus (Lafon & Lawson, 2012).
- Medications including methylnaltrexone and alvimopan are which are peripherally acting mu opioid receptor antagonists have been successful for some patients (Thompson & Magnuson, 2012).

Auscultation of bowel sounds is considered by some to be an inaccurate predictor of the presence of a postoperative ileus. It is possible for a patient to have bowel sounds while still experiencing a lack of bowel motility with other accompanying symptoms of an ileus. Passing flatus and resolution of other symptoms such as abdominal distention, are better indicators of a resolving ileus (Massey, 2012).

Registered nurses need to ensure that the plan of care is followed for the postoperative patient to help prevent an ileus and to follow the revised plan of care if an ileus occurs. Advanced practice nurses should work in collaboration with the surgeon and registered nurses to ensure that the appropriate interventions are being implemented to give the patient the best outcome.

## Conclusion

Postoperative complications cannot be completely eliminated. However, there are many interventions that can be done to help reduce a patient's risk of postoperative complication. Postoperative ileus involves complex pathophysiology and requires a collaboration of the care team to help prevent and treat the condition. Many surgeons have an evidence based bowel protocol that is followed after surgery to restore healthy bowel function in the postoperative patient. The protocol may vary depending on the type of surgery and the patient's specific needs.

An extended hospital stay, postoperative complications, and the symptoms experienced with an ileus can lead to poor patient outcomes and a poor patient experience overall. Nurses play a key role in prevention of an ileus, identification of ileus, and providing care during the recovery period for a postoperative ileus (Lafon & Lawson, 2012). Therefore, nurses must be knowledgeable in the signs and symptoms, pathophysiology, and nursing implications of a postoperative ileus to provide the best care for the postoperative patient.

## References

- Blausen.com Staff. (2014a). Blausen gallery 2014: Anatomy of colon. *Wikiversity Journal of Medicine*. DOI:10.15347/wjm/2014.010. ISSN 20018762.
- Blausen.com Staff. (2014b). Blausen gallery 2014: Anatomy of small intestine. *Wikiversity Journal of Medicine*. DOI:10.15347/wjm/2014.010. ISSN 20018762.
- Bragg, D., El-Sharkawy, A. M., Psaltis, E., Maxwell-Armstrong, C. A., & Lobo, D. N. (2015). Postoperative ileus: Recent developments in pathophysiology and management. *Clinical Nutrition*, 34(3), 367-376 10p. doi:10.1016/j.clnu.2015.01.016
- Fineberg, S. J., Nandyala, S. V., Kurd, M. F., Marquez-Lara, A., Noureldin, M., Sankaranarayanan, S., & ... Singh, K. (2014). Incidence and risk factors for postoperative ileus following anterior, posterior, and circumferential lumbar fusion. *Spine Journal*, 14(8), 1680-1685 6p. doi:10.1016/j.spinee.2013.10.015
- Forrester, D., Doyle-Munoz, J., McTigue, T., D'Andrea, S., & Natale-Ryan, A. (2014). The efficacy of gum chewing in reducing postoperative ileus. *Journal of Wound, Ostomy & Continence Nursing*, 41(3), 227-232 6p. doi:10.1097/WON.000000000000019
- Hadden, K., Prince, L.Y., Schnaekel, A., Couch, C.G., Stephenson, J.M., & Wyrick, T.O. (2016). Readability of patient education materials in hand surgery and health literacy best practices for improvement. *American Society for Surgery of the Hand*, S0363-5023(16)30133-2. doi: 10.1016/j.jhssa.2016.05.006.
- Hiranyakas, A., Bashankaev, B., Seo, C. J., Khaikin, M., & Wexner, S. D. (2011). Epidemiology, pathophysiology and medical management of postoperative ileus in the elderly. *Drugs & Aging*, 28(2), 107-118. doi:10.2165/11586170-000000000-00000.
- Lafon, C., & Lawson, L. (2012). Postoperative ileus in GI surgical patients: Pathogenesis and interventions. *Gastrointestinal Nursing*, 10(2), 45-49 5p.
- Linari, L.R., Schofield, L.C., Horrom, K.A. (2011). Implementing a bowel program: Is a bowel program an effective way of preventing constipation and ileus following elective hip and knee arthroplasty surgery? *Orthopaedic Nursing*, 30(5), 317-21. doi: 10.1097/NOR.0b013e31822c5c10.
- Massey, R. L. (2012). Return of bowel sounds indicating an end of postoperative ileus: is it time to cease this long-standing nursing tradition? *MEDSURG Nursing*, 21(3), 146-150 5p.
- Thompson, M., & Magnuson, B. (2012). Management of postoperative ileus. *Orthopedics*, 35(3), 213-217 5p. doi:10.3928/01477447-20120222-08
- Ward, C. W. (2012). Fast track program to prevent postoperative ileus. *MEDSURG Nursing*, 21(4), 214-222 9p.
- Wronski, S. (2014). Chew on this: Reducing postoperative ileus with chewing gum. *Nursing*, 44(8), 19-23 5p. doi:10.1097/01.NURSE.0000451535.63211.a8

